

Adductor Tendon Repair: Case Report and Description of a Novel Approach for Improved Exposure

Michael Gerhardt, MD,* Benjamin Sherman, DO,† Natasha Trentacosta, MD,* Sarah Hobart, MD,* William Hutchinson, MD,* and Jorge Chahla, MD, PhD*

Summary: Groin pain is one of the most common and challenging diagnoses for a sports medicine physician. Up to 64% of groin injuries involve the adductor tendons, which can be very difficult to treat with or without surgical intervention. The purpose of this article is to report the 2-year outcomes of a patient that presented with an acute proximal adductor tendon injury and to describe a novel surgical approach. This is a case of a 36-year-old elite athlete that presented with an acute adductor longus tear. The patient was treated with surgical repair using a parainguinal approach and bioabsorbable suture anchors into the adductor longus anatomic footprint. The patient had a full return to sport at 8 weeks postoperatively. At 2 years the patient was symptom free and still participating in the same elite level of sport. Adductor repair using a parainguinal approach and bioabsorbable suture anchors is a viable surgical option for patients in the acute setting.

Key Words: groin pain—hip/pelvis/thigh—general sports trauma—muscle injuries.

(*Tech Orthop* 2019;00: 000–000)

Groin pain constitutes a significant cause of morbidity in the athletic population and accounts for up to 6% of all sports-related injuries.¹ Although these injuries can occur in a variety of sports, they tend to occur most commonly in American football players and hockey players.² Injuries to the adductor tendons are especially common and comprise ~64% of groin pathology.³ Adductor tendon injuries typically present as chronic groin pain (on the medial aspect of the thigh) that is exacerbated by exercise. An acute adductor tendon tear may present with an audible pop associated with immediate medial-sided groin pain and ecchymosis.⁴ The diagnosis of adductor tendon pathology relies on history and physical examination findings, aided by noninvasive testing such as ultrasound and magnetic resonance imaging (MRI).⁵ A recent study evaluated the anatomic areas of failure of the adductor tendons in athletes

using MRI. The adductor longus tendon was the most commonly involved tendon (55.9%) with injuries occurring at the proximal insertion in 26%, the musculotendinous junction in 37%, and the distal insertion in 37%.⁶ Of those injuries that occurred at the proximal insertion, 75% were complete avulsion injuries.⁶

Partial and distal avulsions of the adductor longus have been shown to heal without surgical intervention; however, the treatment of proximal avulsions with or without osseous components remains controversial.⁷ Advocates for both nonsurgical and surgical treatment exist with most favoring nonoperative intervention as literature has failed to show improvement in function or expedited return to play after surgical repair.⁸ The surgical repair techniques reported in the literature utilize an incision distal to the medial portion of the inguinal ligament in the distal groin skin crease.⁷ This approach allows for easy identification of the tendinous stump (which is located distally near the incision line), however, it does not allow for easy visualization of the bony footprint or identification of “at risk” structures. A more proximal-based incision that is typical for an inguinal hernia repair allows for improved exposure and may ultimately lead to a stronger and safer repair. The purpose of this article was to report on a patient that presented with an acute proximal adductor tendon injury that was repaired using an alternative approach through a parainguinal incision.

CASE REPORT

Patient History

The patient is a 36-year-old male elite discus thrower who presented 4 days after sustaining an injury to his right groin while squatting over 300 pounds. At the time of injury, he felt a pop and experienced immediate pain in the right groin and adductor region. After the injury, he continued to have severe pain and swelling in the right groin region and adductor, limiting his activities.

Physical Examination

On physical examination, the day following the injury, the patient was noted to have extensive ecchymosis in the right medial thigh and inguinal region. He was tender to palpation over the proximal right adductor complex extending up to the pubic tubercle. A palpable defect or mass could not be readily appreciated, however significant soft tissue swelling was noted in proximal adductor and inner thigh areas.

Imaging

Hip and pelvis radiographs were obtained in the office showing normal anatomic alignment with well-maintained joint spaces of both hips and no evidence of avulsion fracture in the zone of injury. An MRI was ordered and revealed a complete rupture of the adductor longus with 3 cm of distal retraction. A large hematoma was noted measuring 3.0×2.0×1.5 cm in addition to increased signal surrounding the adductor brevis, pectineus, and adductor magnus (Fig. 1).

Treatment options were presented to the patient including operative (adductor tendon repair) and nonoperative approaches. Given the patient’s athletic background and desire to return to his previous level of

From the *Cedars Sinai, Kerlan-Jobe Institute, Santa Monica Orthopaedic and Sports Medicine Group, Santa Monica; and †Riverside University Health System, Moreno Valley, CA.

M.G.: is a paid consultant for Arthrex. Royalties Arthrex. Research grants Arthrex. Consultant Medacta. Shareholder Kerlan Jobe institute. Hospitality funding from Stryker. N.T.: has received hospitality funding from Medical Device Businesses Services Inc. and hospitality and educational funding from Arthrex Inc., Smith and Nephew, DJO and Depuy Synthes. Research grants from DJO and Arthrex. S.H.: has received education funding from Arthrex Inc. and Smith and Nephew. Research grants from Arthrex Inc. W.H.: has received educational support and hospitality funding from Intuitive Surgical. The remaining authors declare that they have nothing to disclose.

For reprint requests, or additional information and guidance on the techniques described in the article, please contact Michael Gerhardt, MD, at mgerhardt@smog-ortho.net or by mail at Cedars Sinai, Kerlan-Jobe Institute, Santa Monica Orthopaedic and Sports Medicine Group, Santa Monica, CA 90404. You may inquire whether the author(s) will agree to phone conferences and/or visits regarding these techniques.

Copyright © 2019 Wolters Kluwer Health, Inc. All rights reserved.

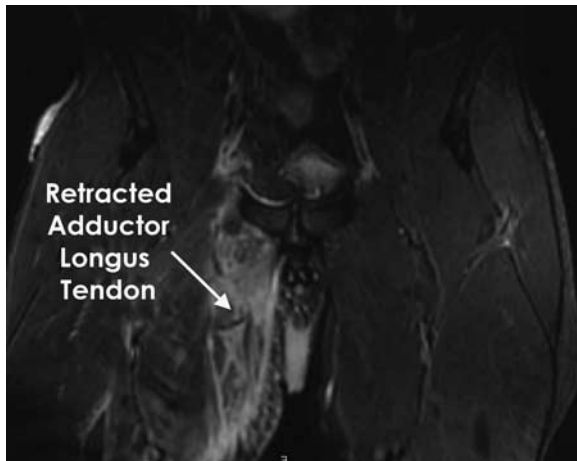


FIGURE 1. Magnetic resonance imaging (coronal cut) demonstrating a complete rupture of the adductor longus with 3 cm of distal retraction. A large hematoma can be observed in addition to increased signal surrounding the adductor brevis, pectineus, and adductor magnus.

sports participation in a timely manner, he decided to proceed with surgical intervention.

Surgical Technique

The patient was placed supine on the operating room table and given a general anesthetic. The right groin region was prepped and draped in a sterile manner. A 5 cm parainguinal incision was marked 2 cm proximal to the pubic tubercle running along the inguinal crease (Fig. 2).

The patient was injected lateral to the incision with 10 mL of 1% lidocaine with epinephrine in order to block the ilioinguinal nerve, iliohypogastric nerve and the area of the adductor insertion. Incision was made and the dissection was carried down to the external oblique fascia (Fig. 3).

An exploration of the region was undertaken by a board-certified general surgeon to identify the superficial inguinal ring, ilioinguinal nerve, genital branch of genitofemoral nerve, branch of the iliohypogastric nerve, and rectus abdominus insertion. The external oblique fascia was divided carefully to expose the inguinal canal and the spermatic cord (Fig. 4).

With the spermatic cord retracted and protected superiorly, the adductor injury was visualized and addressed. The adductor tubercle can be easily palpated at this point, just inferior to the rectus insertion. Approximately 1 cm distal and lateral to the tubercle the footprint of the adductor longus tendon can be identified. The overlying spermatic cord

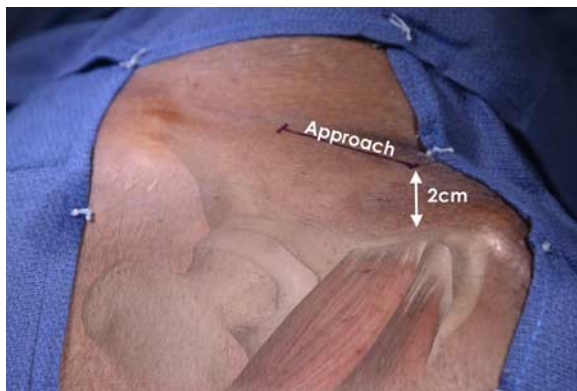


FIGURE 2. Picture demonstrating the surgical approach for a right-sided adductor longus repair. A 5 cm parainguinal incision is planned, 2 cm proximal to the pubic tubercle running along the inguinal crease. [full color online](#)

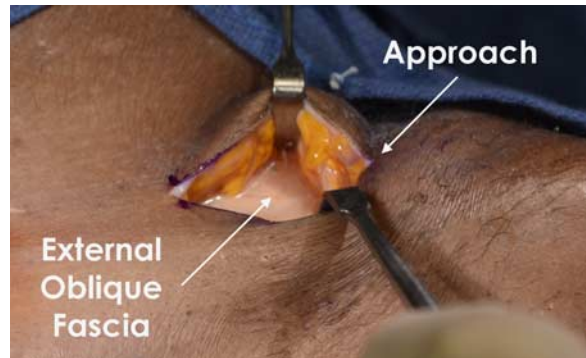


FIGURE 3. Photograph of the deep surgical approach for an adductor longus repair in a right hip. Sharp dissection and meticulous hemostasis should be performed until the external oblique fascia is identified. [full color online](#)

was carefully retracted proximally, thus exposing the zone of injury (Fig. 5).

After palpating the pubic tubercle, the overlying adductor fascia was identified. The fascia is typically intact and needs to be carefully incised and dissected to find the adductor longus tendon and its bony attachment. A longitudinal incision through the thick adductor fascial sheath revealed a moderately sized seroma/hematoma consistent with a recent avulsion injury. The retracted adductor tendon was then identified and all adhesions hindering its mobilization were bluntly released in order to obtain adequate tendinous excursion. The tendon was tagged and set aside at this point (Fig. 6).

Next, the bony bed was prepared with care taken to preserve all the neurovascular structures in the area. The anterior and posterior divisions of the obturator nerve enter just lateral to the adductor complex (in close proximity to the zone of injury) and should be avoided. All soft tissue remnants from the superior pubic ramus footprint were meticulously removed with a curette and rongeur allowing for a healthy osseous bed for reattachment of the tendon (Fig. 7).

To optimize healing potential, several small micropick puncture holes were placed in the bed to augment the repair with bone marrow growth factors. Next, the bioabsorbable suture anchors were placed (double loaded 4.5 mm Biocomposite double loaded Corkscrew anchors; Arthrex, Naples, FL), after punching and tapping the bone (Fig. 8).

Using a single limb of suture, a modified Krakow stitch was placed in a running interlocking pattern. The other end of the same suture strand was used to apply tension, which effectively reduced the tendon to the bony footprint and standard knots were tied and secured. This suture sliding technique was used for each of the sutures in the corresponding anchors. In this case, 2 suture anchors were required. The area was then copiously irrigated with saline. The adductor sheath was then loosely closed superficially to the repair site using #1 vicryl suture.

Next, the external oblique muscle was closed using a running 2-0 vicryl, with care taken to protect the spermatic cord and underlying neurovascular structures. The subcutaneous tissue was then closed with

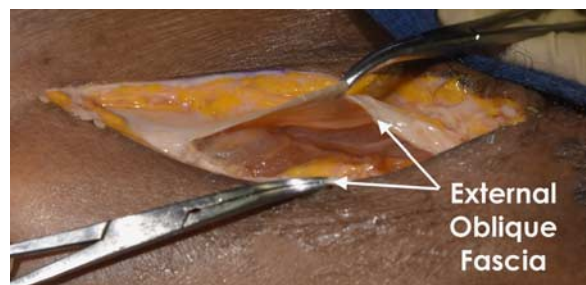

FIGURE 4. Intraoperative picture showing the external oblique fascia divided transversally (in line with its fibers), exposing the inguinal canal. [full color online](#)

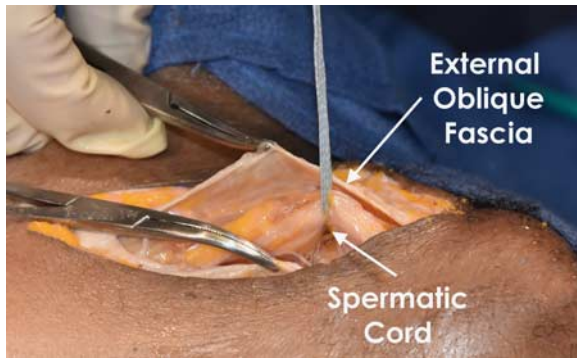


FIGURE 5. Picture demonstrating the identification and proximal retraction of the spermatic cord, to avoid iatrogenic damage to this structure. [full color online](#)

3-0 vicryl and the skin with 4-0 monocryl. Dermabond was then applied to the incision site as a final sealant over the wound and covered with a telfa and tegaderm dressing.

RESULTS

Postoperative Course

The patient was discharged from the outpatient surgery center with instructions to remain partial weight-bearing with crutches on the operative extremity. Hip range of motion was encouraged from 0 to 90 degrees of flexion with passive adduction as tolerated. Active adduction was restricted for the first 2 postoperative weeks. The patient was seen on postoperative day 7 and his weight-bearing status advanced as tolerated. A home exercise program was started after the first office visit with isometric hip exercises in extension, abduction, and external rotation. He was able to return to independent ambulation on postoperative day 10. Stationary bike instituted at beginning of week 2. Antigravity jogging at week 3 and standard jogging at week 4. Strength training and agility initiated at 5 to 6 weeks. Return to modified training at 6 weeks with clearance to full training at 8 weeks. At 2-year follow-up, the patient was symptom free and had continued to participate in elite level track and field events.

DISCUSSION

This case report provides a detailed surgical technique and follow-up of a high-level athlete that underwent proximal

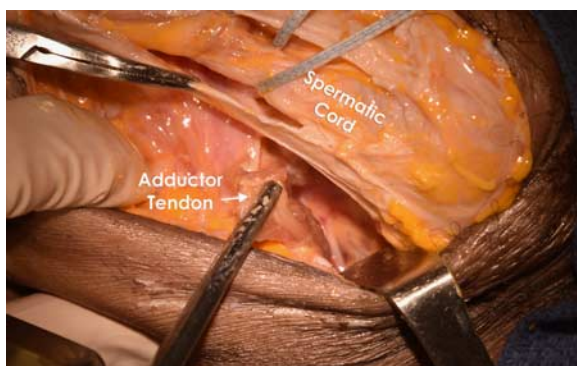


FIGURE 6. Picture demonstrating the identification of the retracted adductor tendon. It is important to bluntly release all adhesions to allow for adequate tendinous excursion to reach the footprint. [full color online](#)

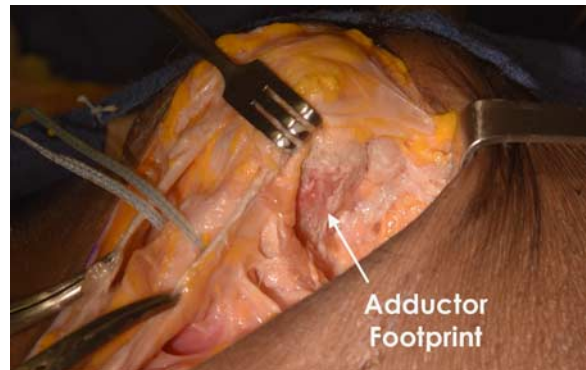

FIGURE 7. Intraoperative photograph demonstrating the bony bed prepared for reattachment of the adductor tendon. All soft tissue remnants from the superior pubic ramus footprint should be meticulously removed with a curette and rongeur allowing for a healthy osseous bed for reattachment of the tendon. [full color online](#)

adductor repair with a novel surgical approach that significantly improves visualization of the anatomic footprint. Complete ruptures of the proximal adductor longus tendon are relatively uncommon injuries with scattered case reports throughout the literature.⁷⁻¹⁵ These injuries tend to occur in male athletes in sports requiring quick cutting or pivoting maneuvers, shooting, or kicking such as soccer, football, ice hockey, or rugby. Occasionally “blowout” injuries can occur in weight lifting athletes as presented in this case report.

The typical mechanism of failure involves an eccentric overloading of the muscle caused by forced abduction of the contracting adductor muscle. Although uncommon, when these injuries occur in elite athletes, the consequences can be significant and often result in lost playing time. These injuries can be difficult to distinguish from a typical groin strain. However, it is common to mistake adductor avulsions with groin strains and thus it is important to have a high index of suspicion in patients presenting with acute groin pain following a sports injury. MRI remains the most reliable and useful imaging study to confirm the diagnosis (86% sensitivity and 89% of specificity).⁵

Given its low incidence, reports on the treatment of adductor ruptures are scarce.^{7-9,11,14,15} In following nonoperative treatment of adductor longus ruptures with serial ultrasound examinations, Thorborg et al¹² reported that after 4 to 6 weeks, calcifications appear at the insertion site and after 18 weeks, inflammation decreases in the area, which the authors conclude likely coincides with healing. A series of 19 NFL players with proximal adductor

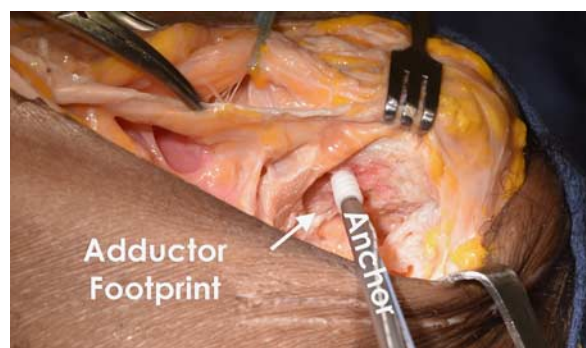


FIGURE 8. Intraoperative photograph demonstrating a bio-absorbable suture anchor being inserted in the anatomic footprint (double loaded 4.5 mm Biocomposite double loaded Corkscrew anchors), after punching and tapping the bone. [full color online](#)

longus ruptures was reported by Schlegel et al⁸ who found a faster return to play with nonoperative management compared with open repair of the adductor tendon with suture anchors. However, this study has been scrutinized as it was a retrospective review, with only 5 operative patients (underpowered) and no objective data at final follow-up. Further, patients were not categorized for the treatment (28% of the patients in the nonoperative group had > 3 cm of retraction, whereas 60% of the patient in the operative group had > 3 cm of retraction).

The traditional approach described for the repair of proximal adductor avulsions is a more distally based incision in the distal groin crease with proximal blunt dissection to the tendon and its footprint. Given the proximity of the neurovascular (obturator and inguinal nerves) and reproductive (spermatic cord) structures to the adductor origin, there is a theoretical risk of injury, however the authors are not aware of any documented case of these complications. In our practice, we have found that it is not uncommon for patients with adductor pathology to have concomitant injuries to the rectus abdominus, defects in the inguinal canal and entrapment of the inguinal nerves. These injuries are difficult to diagnose preoperatively but should be considered in patients presenting with a component of chronic inguinal-related groin pain. Furthermore, direct visualization of the bony footprint reduces the risk of missing partial tears or associated pathology (rectus abdominus tears, sports hernias) that could potentially result in less than optimal and/or nonanatomic repairs. With the technique described in this report, the surgeon can confidently address any associated pathology, while minimizing the risk of complications through direct visualization of neurovascular or reproductive structures. In addition, improved visualization of the anatomic footprint of the adductor longus tendon reduces the risk of an insecure or nonanatomic repair, potentially translating into a more rapid recovery and expedited return to training and play.

Complications have been reported with both operative and nonoperative management. One case report showed the development of enthesophyte formation in an elite rugby player who sustained an adductor longus rupture and suffered continual pain despite nonoperative treatment. This required eventual surgery and removal of the enthesophyte without incident.¹³ There can also be a delayed or incomplete return of strength as compared with operative intervention. Concerns with operative intervention, regardless of the approach, involve not only risks inherent to surgical intervention, particularly surgical site infection, but also the neurovascular structures adjacent to the adductor footprint, including the spermatic cord. Banks et al¹¹ reported on 2 cases of chronic infections following surgical repair of adductor longus ruptures and cautioned operative management for this injury. In addition, neurovascular injury is a recognized risk of surgery in the inguinal and adductor region. In this regard, the spermatic cord, the ilioinguinal nerve, the genital nerve, and the obturator nerve are in close proximity to the adductor tendon and should be carefully protected. In addition, without careful dissection and repair, an iatrogenic hernia may be produced.

The extensive time required for return of strength and function of the adductor muscle following both operative and nonoperative intervention has also been well documented in the literature. A previous case report on operative fixation of an adductor longus rupture documented normalized hip adductor strength at 8 weeks postoperatively and return to previous competitive play at 10 weeks postoperatively.¹⁴ Thorborg et al¹² reported on a single soccer player who sustained bilateral adductor longus ruptures separated by 10 months that were

treated nonoperatively. This player was able to return to competitive play 15 weeks following the first injury and 12 weeks following the second injury. The player saw normalization of his adductor strength after 6 months with his first injury and 10 weeks after his second injury. The adductor muscle group has been shown to be important in stabilization during cutting movements and its loss of function may adversely affect players in sports which rely on such movements.¹⁶ The argument for surgical fixation of adductor longus ruptures, especially in athletes, is the potential for returning the player back to a high level of play with little to no deficit in function and ideally at an equal or faster rate than nonoperative management. The literature has shown poor outcomes following adductor tenotomy for chronic pain in high-level athletes, with decreased muscle strength and level of activity.^{17,18} Also, theoretically the post-injury hematoma may lead to complications such as myositis ossificans, as mentioned above, and surgery allows for evacuation of this fluid collection.

CONCLUSIONS

Treatment for acute adductor longus avulsions should be individualized based on patient and injury characteristics. A high index of suspicion is needed for diagnosis as these injuries are commonly missed. When operative intervention is required, using a parainguinal approach allows improved visualization of the tendon footprint with the ability to address simultaneous pathology and protect nearby anatomic structures. This approach allows for an anatomic, robust repair that can promote early return to play. However, it is still important to realize each patient is unique and their presentation as well as their goals should be taken into account when deciding on treatment options. Further research, with well-powered clinical randomized trials and objective outcome measures are needed to determine the best approach for these athletes.

REFERENCES

1. Suarez JC, Ely EE, Mutnal AB, et al. Comprehensive approach to the evaluation of groin pain. *J Am Acad Orthop Surg.* 2013;21:558–570.
2. Uebelacker P, English B, Mueller-Wohlfahrt HW. Nonoperative treatment and return to play after complete proximal adductor avulsion in high-performance athletes. *Knee Surg Sports Traumatol Arthrosc.* 2016;24:3927–3933.
3. Werner J, Hagglund M, Walden M, et al. UEFA injury study: a prospective study of hip and groin injuries in professional football over seven consecutive seasons. *Br J Sports Med.* 2009;43:1036–1040.
4. Hopkins JN, Brown W, Lee CA. Sports hernia: definition, evaluation, and treatment. *JBJS Rev.* 2017;5:e6.
5. Omar IM, Zoga AC, Kavanagh EC, et al. Athletic pubalgia and “sports hernia”: optimal MR imaging technique and findings. *Radiographics.* 2008;28:1415–1438.
6. Serner A, Weir A, Tol JL, et al. Characteristics of acute groin injuries in the adductor muscles: a detailed MRI study in athletes. *Scand J Med Sci Sports.* 2018;28:667–676.
7. Vogt S, Ansah P, Imhoff AB. Complete osseous avulsion of the adductor longus muscle: acute repair with three fiberwire suture anchors. *Arch Orthop Trauma Surg.* 2007;127:613–615.
8. Schlegel TF, Bushnell BD, Godfrey J, et al. Success of nonoperative management of adductor longus tendon ruptures in National Football League athletes. *Am J Sports Med.* 2009;37:1394–1399.
9. van de Kimmenade RJ, van Bergen CJ, van Deurzen PJ, et al. A rare case of adductor longus muscle rupture. *Case Rep Orthop.* 2015;2015:840540.

10. Aerts BR, Plaisier PW, Jakma TS. Adductor longus tendon rupture mistaken for incarcerated inguinal hernia. *Injury*. 2014;45:639–641.
11. Banks DBA, MacLennan I, Banks AJ. Adductor longus ruptures in elite sportsmen—pitfalls of surgical repair: a report of two cases. *BMJ Case Rep*. 2013;2013:bcr2013010073.
12. Thorborg K, Petersen J, Nielsen MB, et al. Clinical recovery of two hip adductor longus ruptures: a case-report of a soccer player. *BMC Res Notes*. 2013;6:205.
13. Dimitrakopoulou A, Schilders E, Bismil Q, et al. An unusual case of enthesophyte formation following an adductor longus rupture in a high-level athlete. *Knee Surg Sports Traumatol Arthrosc*. 2010;18:691–693.
14. Dimitrakopoulou A, Schilders EM, Talbot JC, et al. Acute avulsion of the fibrocartilage origin of the adductor longus in professional soccer players: a report of two cases. *Clin J Sport Med*. 2008;18:167–169.
15. Rizio LI, Salvo JP, Schürhoff MR, et al. Adductor longus rupture in professional football players: acute repair with suture anchors a report of two cases. *Am J Sports Med*. 2004;32:243–245.
16. Neptune RR, Wright IC, van den Bogert AJ. Muscle coordination and function during cutting movements. *Med Sci Sports Exerc*. 1999;31:294–302.
17. Akermark C, Johansson C. Tenotomy of the adductor longus tendon in the treatment of chronic groin pain in athletes. *Am J Sports Med*. 1992;20:640–643.
18. Martens MA, Hansen L, Mulier JC. Adductor tendinitis and musculus rectus abdominis tendopathy. *Am J Sports Med*. 1987;15:353–356.