

# Intra-articular psoas tendon release alters fluid flow during hip arthroscopy

Bryan T. Hanypsiak<sup>1,2</sup>, Marc A. Stoll<sup>2</sup>, Michael B. Gerhardt<sup>3</sup>, Jeffrey M. DeLong<sup>2</sup>

<sup>1</sup> Mount Sinai Hospital, New York - USA

<sup>2</sup> Arthrex Inc., Naples, Florida - USA

<sup>3</sup> Santa Monica Orthopaedic and Sports Medicine Group, Santa Monica, California - USA

**ABSTRACT:** While not proven definitively, the hypothesis that intra-articular psoas tendon release allows fluid to track into the retroperitoneal space has been widely accepted. This study attempts to identify the path through which fluid enters the pelvis and retroperitoneal space.

Six hemi-pelvis human cadaveric specimens were utilized for this study. 3 specimens underwent a capsulotomy and psoas tendon release, while 3 had only a capsulotomy. Arthroscopy fluid was combined with Barium and Methylene blue, and fluid was run at 50 mmHg for 2 hours. A gross dissection was performed at the end of the arthroscopy and the path of fluid flow into the pelvis and throughout the thigh was identified.

All 6 specimens showed extravasation of fluid into the pelvis at the 5 minute mark. Specimens with a psoas tendon release showed an altered pattern of fluid flow. In all three of these specimens, the psoas muscle belly was bright blue, along with the remaining tendon. Two of the 3 specimens showed tracking of fluid along the vasculature in both directions. The volume of fluid tracking into the pelvis was increased following a psoas release.

Arthroscopy fluid rapidly enters the pelvis following the initiation of hip arthroscopy, regardless of the status of the psoas tendon. Release of the psoas tendon allows fluid to diffuse into the psoas muscle and anterior medial thigh, tracking both proximally and distally along the neurovascular structures, and the volume of fluid tracking into the pelvis is increased following a psoas release.

**KEY WORDS:** Hip arthroscopy, Fluid extravasation, Psoas tendon release

Accepted: August 13, 2012

## INTRODUCTION

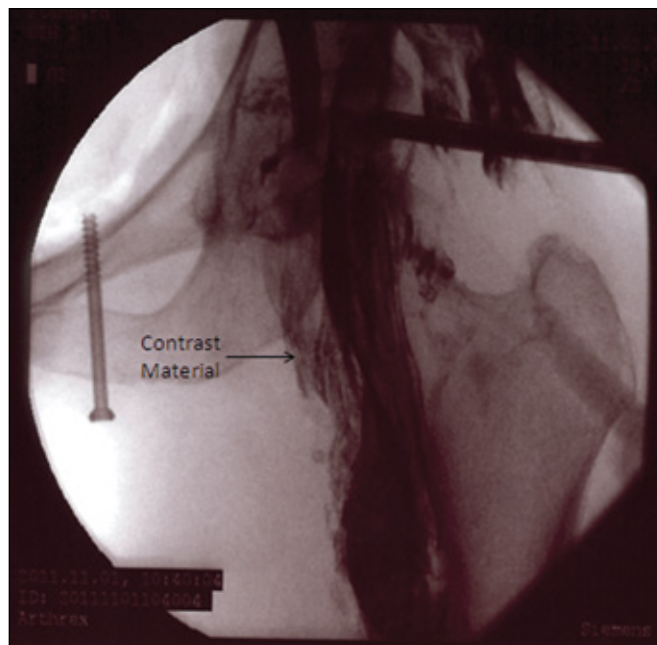
Abdominal compartment syndrome is a rare, but serious complication of hip arthroscopy. Most commonly reported in patients with acetabular fractures (1), it has also been reported during routine hip arthroscopy. As more such procedures are performed and the duration and complexity increases, it is likely more cases will be reported (2). While not proven definitively, the hypothesis that intra-articular psoas tendon release allows fluid to track into the retroperi-

toneal space has been widely accepted (3). Many surgeons have altered the timing of their psoas release to limit fluid extravasation. This study attempts to identify the path through which fluid enters the pelvis and retroperitoneal space.

## MATERIALS AND METHODS

Six hemi-pelvis human cadaveric specimens were utilized for this study. The hips were prepared with 3 pins in the

iliac wing and one in the middle 1/3 of the femoral shaft. The pelvis pins were suspended on a table clamp and the femoral shaft pin was attached to a bow. A nylon ratcheting wrench was attached to the bow and traction was applied to obtain distraction. An x-ray image intensifier (C-arm) Siemens (Siemens Inc. Munich, Germany) Siremobil Compact set at 43 KV and 0.2 ma to verify adequate joint distraction of approximately 1 cm. We then established a standard anterior lateral portal at the anterior superior corner of the greater trochanter with a 14 gauge spinal needle under fluoroscopic guidance. A flexible 1.5 mm nitinol wire was inserted through the spinal needle into the central compartment. Sequential dilation is performed using both a tapered 4 mm and 6 mm dilator (Arthrex, Inc. Naples, Florida). A 70 degree arthroscope (Karl Storz, Munich, Germany) was then inserted into the joint over the 4 mm dilator. After visual confirmation of successful joint access, the scope was used to visualize the anterior capsule. This was performed without fluid to enhance visualization until an outflow could be established. A mid anterior portal was then created under direct visualization to prevent iatrogenic damage to the anterior labrum. A 14 gauge spinal needle was then placed through the anterior capsule, and the previously described dilation process was repeated. Once the mid anterior portal was created, flow was begun and a banana blade (Arthrex, Inc. Naples, Florida) was introduced into the joint and a capsulotomy, connecting the two portals, was performed. In three specimens, an intraarticular psoas tendon release was performed by extending the capsulotomy to the psoas notch, identifying the undersurface of the tendon, and releasing it with a 90 degree Cool Cut OPES ablator (Arthrex, Inc. Naples, Florida). We then introduced an 8.25 mm partially threaded translucent twist-in cannula (Arthrex, Inc. Naples, Florida) into the mid anterior portal in all six specimens and confirmed intraarticular placement with the scope. We utilised a Continuous Wave III arthroscopy pump (Arthrex, Inc. Naples, Florida) set at 50 mm Hg pressure and 100% flow. We then prepared our irrigation with 5 gallons of saline mixed with a suspension of barium sulfate and methylene blue (MeBlue = 10 mg MeBlue/20 mL DI H<sub>2</sub>O BaSulfate = 50 g BaSO<sub>4</sub>/4L Tap H<sub>2</sub>O). The irrigation was manually stirred every 10 minutes to maintain the mixture. The irrigation tubing was connected to the arthroscope cannula and maintained in the anterior lateral portal. The 8.25 mm partially threaded twist-in cannula was maintained in the



**Fig. 1** - Radiograph demonstrating fluid extravasation (black arrow) into the pelvis in a specimen with a capsulotomy and iliopsoas release.

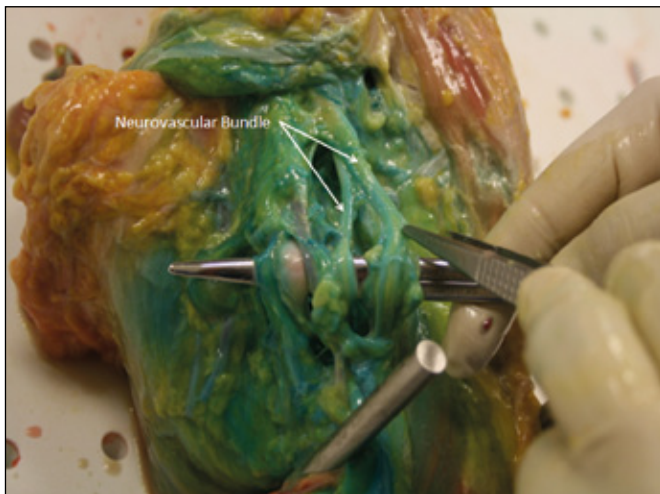
mid anterior portal. The irrigation was allowed to run continuously for 2 hours.

C-arm images were obtained on each specimen at 5 minute intervals during the two hour trial, and the location of the barium was noted. Arthroscopy fluid on the table and exterior thigh was removed with a towel prior to each image to improve clarity.

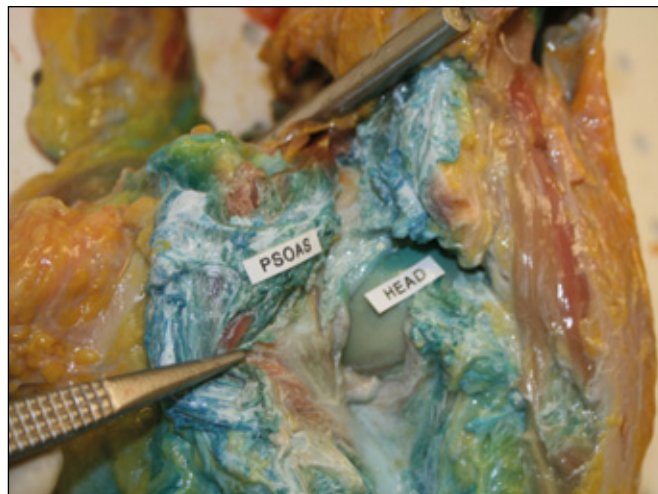At the two hour mark, the fluid was turned off, and a gross dissection of the specimen was performed to determine the exact anatomic location of the methylene blue.

## RESULTS

All 6 specimens showed extravasation of fluid into the pelvis at the 5 minute mark. The fluid travelled over the anterior medial acetabulum, underneath the psoas tendon, and into the pelvis. As expected, barium was concentrated around the portals in the thigh in all specimens. Images of the three specimens that had a transcapsular release of the iliopsoas tendon showed a broader pattern of dispersion and increased volume of flow into the pelvis (Fig. 1).



**Fig. 2** - Fluid extravasation affecting the neurovascular bundle (stained in blue) in a specimen with a capsulotomy and iliopsoas release.



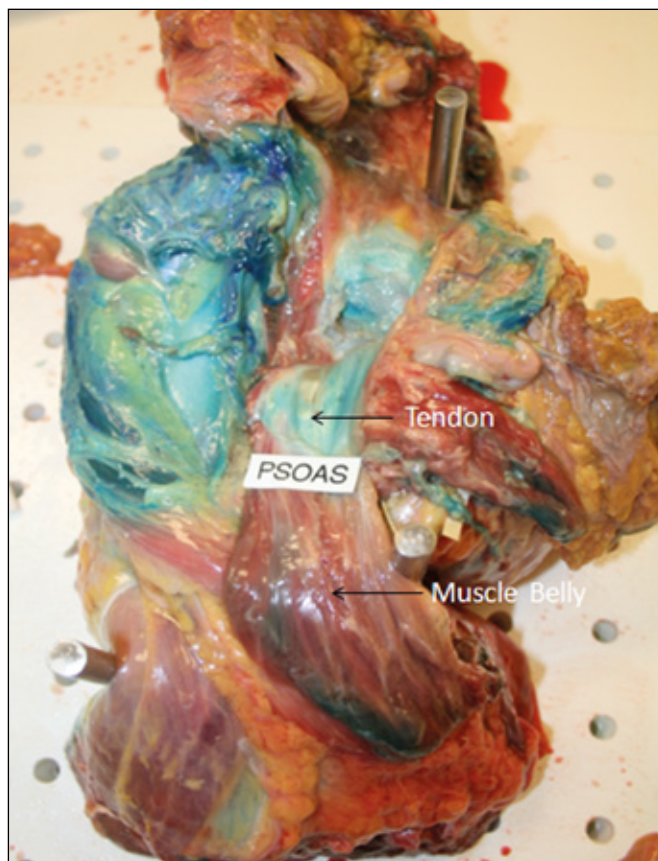
**Fig. 3** - Extravasation of contrast material (stained in white and blue) of the psoas muscle belly in a specimen with a capsulotomy and iliopsoas release.

On dissection, 2 of the specimens had extravasation of fluid affecting the neurovascular bundle (Fig. 2) and all 3 specimens had extravasation of fluid into the psoas muscle belly (Fig. 3).

On dissection, capsulotomy only specimens showed a bright blue psoas tendon (Fig. 4), but the psoas muscle itself was unaffected. A clear track of blue could be seen travelling throughout the path of each portal and throughout associated muscles. The lateral femoral cutaneous nerve was dyed blue in each of the six specimens. The retroperitoneal space was filled with blue fluid, travelling from underneath the psoas tendon, over the acetabulum and connective tissues and down into the pelvis. The abdominal cavity and neurovascular structures of the thigh were spared.

Dissecting the specimens with psoas tendon release showed an altered pattern of fluid flow. In all three specimens, the psoas muscle belly was bright blue, along with the remaining tendon. Two of the three specimens showed tracking of fluid along the vasculature in both directions, staining the nerve, vessels and lymphatics bright blue. One specimen showed staining of only the most medial portion of the nerve.

During the dissection, it became immediately obvious that an intact tendon serves to funnel the fluid away from the anterior medial thigh, whereas a released tendon allowed more rapid inflow of fluid. Extravasation of fluid into the pelvis was immediate and occurred independently of the status of the psoas tendon.



**Fig. 4** - A specimen with a capsulotomy only demonstrating involvement of the psoas tendon (stained in blue) without involvement of the psoas muscle belly.

## DISCUSSION

Fluid extravasation into the abdominal and thoracic cavities has been reported in the literature. Barlett et al reported the first case of abdominal compartment syndrome following hip arthroscopy for removal of a loose body in 1998 (1). The patient suffered cardiac arrest and prolonged anoxia after a hip arthroscopy, requiring emergent decompression of his abdomen. In 2010, there were three published case reports of symptomatic fluid extravasation following hip arthroscopy. Verma and Sekiya reported intrathoracic fluid extravasation after elective hip arthroscopy of a 21-year-old woman who underwent an osteoplasty and iliopsoas lengthening (4). Ladner et al reported abdominal fluid extravasation after a hip arthroscopy in a 42-year-old woman who underwent a synovectomy, limited capsulotomy, debridement of an irreparable labral tear, chondroplasty, and osteoplasty of the femoral head-neck junction (5). Lastly, Fowler and Owens reported abdominal compartment syndrome after hip arthroscopy of a 42-year-old man who underwent a psoas tenotomy and debridement of the labrum and pincer lesion. This patient required an emergency exploratory laparotomy. During the laparotomy an obvious fluid track was noted along the iliopsoas muscle and iliac vessels (6). These findings were confirmed in our study. Following review of the c-arm images and dissection of the specimens, we were able to conclude that arthroscopy fluid rapidly enters the pelvis following the initiation of hip arthroscopy. Release of the psoas tendon allows fluid to diffuse into the psoas muscle and anterior medial thigh, tracking both proximally and distally along the neurovascular structures. The volume of fluid tracking into the pelvis is increased following a psoas release, perhaps due to the creation of a larger potential space. Based on this study, the authors recommend when indicated, performing an intra-articular psoas tendon release just prior to conclusion of the case.

One limitation of the study is the use of the hemi pelvis. After flowing into the retroperitoneal space, the fluid could escape and run onto the laboratory table. Although the methylene blue and barium provided clear evidence of the fluids path, and the volume was obviously greater in the psoas tendon release, the exact volume of fluid entering the pelvis could not be quantified. Our next experimental design will include the use of full cadaveric specimens to determine the exact volume and timing of fluid entering the retroperitoneal space. Future studies are planned to look at the effects of altered pump pressure, the use of a posterior outflow portal, and the use of a pressure sensitive pump to reduce fluid flow into the soft tissues surrounding the hip.

## CONCLUSION

Arthroscopy fluid rapidly enters the pelvis following the initiation of hip arthroscopy, regardless of the status of the psoas tendon. Release of the psoas tendon allows fluid to diffuse into the psoas muscle and anterior medial thigh, tracking both proximally and distally along the neurovascular structures and the volume of fluid tracking into the pelvis is increased following a psoas release.

*Financial support: No financial support was received for this study.*

*Conflict of interest: Bryan T. Hanypsiak, MD receives royalties from Frantz Medical, 7740 Metric Drive, Mentor, Ohio 44060, USA. Michael B. Gerhardt, MD is a consultant for the following: Genzyme Inc, Cambridge, MA 02142; Arthrex Inc, Naples, FL 34108; Express Therapy, Santa Monica, CA 90404; Zimmer Inc, Warsaw, IN 46580, USA.*

Address for correspondence:  
Bryan Hanypsiak, MD  
1370 Creekside Boulevard  
Naples, Florida 34108-1945, USA  
warthog23@mac.com

---

## REFERENCES

1. Bartlett CS, DiFelice GS, Buly RL, Quinn TJ, Green DS, Helfet DL. Cardiac arrest as a result of intraabdominal extravasation of fluid during arthroscopic removal of a loose body from the hip joint of a patient with an acetabular fracture. *J Orthop Trauma*. 1998;12:294-9.
2. Awan N, Murray P. Role of hip arthroscopy in the diagnosis and treatment of hip joint pathology. *Arthroscopy*. 2006;22:215-8.
3. Haupt U, Völkle D, Waldherr C, Beck M. Intra- and retroperitoneal irrigation liquid after arthroscopy of the hip joint. *Arthroscopy*. 2008;24:966-8.
4. Verma M, Sekiya JK. Intrathoracic fluid extravasation after hip arthroscopy. *Arthroscopy*. 2010;26(suppl):S90-4.
5. Ladner B, Nester K, Cascio B. Abdominal fluid extravasation during hip arthroscopy. *Arthroscopy*. 2010;26:131-5.
6. Fowler J, Owens BD. Abdominal compartment syndrome after hip arthroscopy. *Arthroscopy*. 2010;26:128-30.